

# AXILLARY BRACHIAL PLEXUS BLOCK LANDMARK TECHNIQUES TUTORIAL OF THE WEEK 165

11<sup>TH</sup> JANUARY 2010

Dr Z Harclerode, Dr S Michael  
Northern General Hospital, Sheffield, UK  
Correspondence to [steliosmichael@sth.nhs.uk](mailto:steliosmichael@sth.nhs.uk)



---

## QUESTIONS

Before continuing, try to answer the following questions. The answers can be found at the end of the article, together with an explanation.

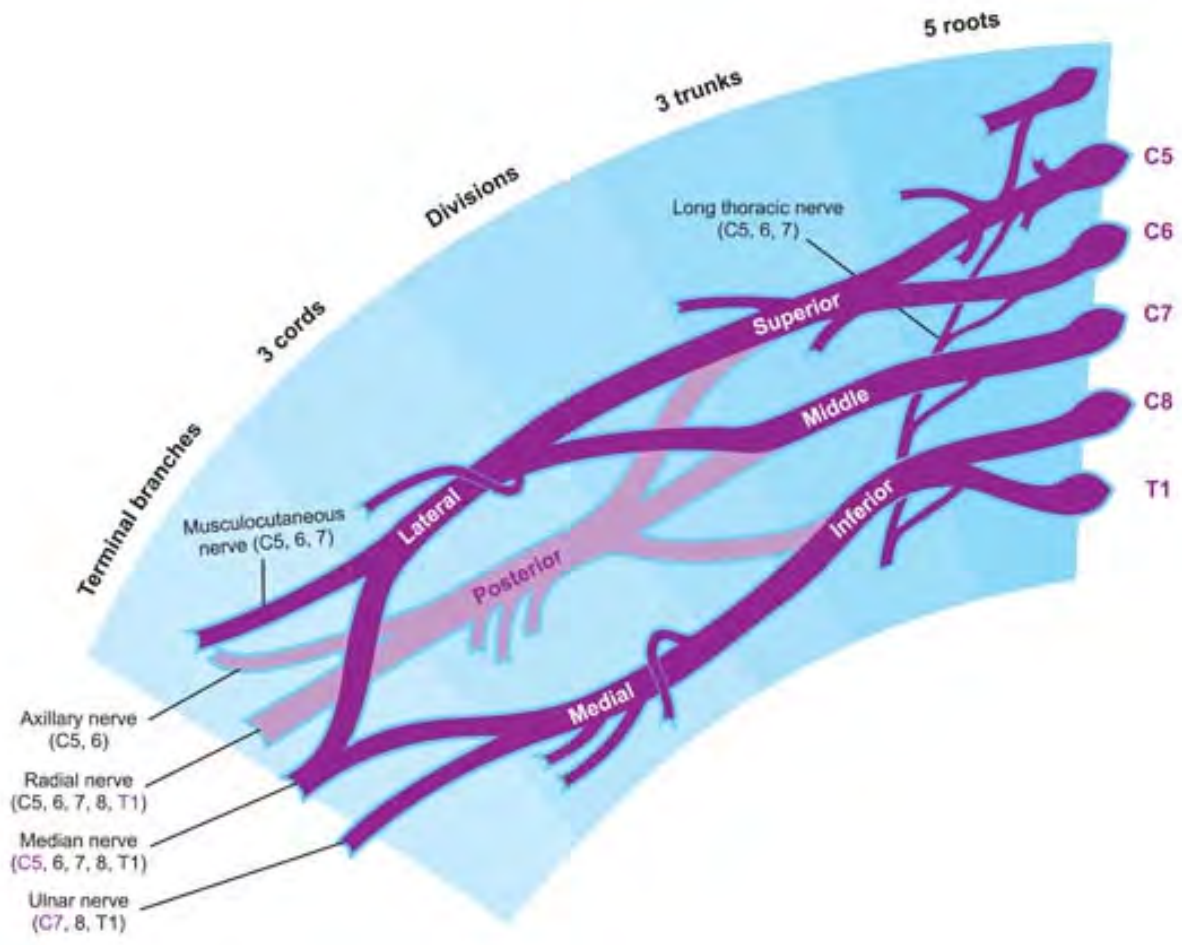
1. Which of the following statements is correct?
  - a. The median nerve is outside the axillary sheath and is easily missed
  - b. The brachial plexus is formed from the nerve roots of C3-T1
  - c. The cords are named according to their arrangement around the axillary artery
  - d. The ulnar nerve supplies the extensor muscles of the hand and forearm
2. Name three absolute contraindications to performing an axillary plexus block
3. Which of the following statements is false?
  - a. When using a peripheral nerve stimulator, intraneural injection is reduced by lack of motor response at 0.3mA
  - b. A multiple stimulation technique has a higher success rate for axillary blocks than a single stimulation technique
  - c. Blocking the intercostobrachial nerve can decrease upper limb tourniquet pain
  - d. 0.375% Bupivacaine can give analgesia for up to 14-16 hours.

## INTRODUCTION

The axillary brachial plexus block is a popular nerve block for forearm, wrist and hand surgery. It can be used to provide regional anaesthesia or as an analgesic technique to be used in combination with general anaesthesia. It has the advantage of being performed away from the pleura and neuraxial structures. The block was first described in New York in 1884 by Halstead, being performed using cocaine under direct vision of the plexus. The first percutaneous block was described in 1911 by Hirschel.

## ANATOMY

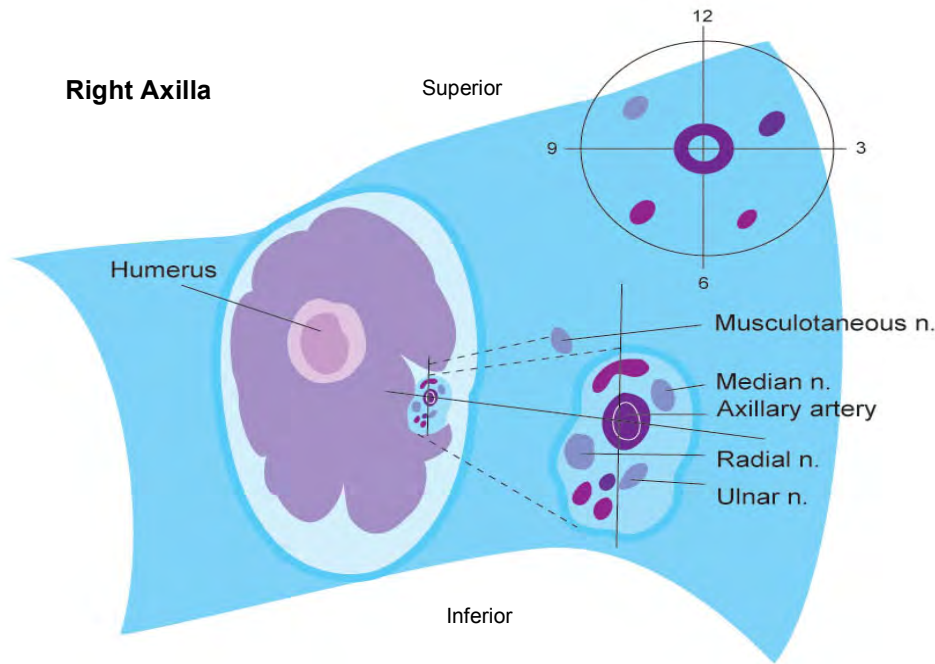
### Brachial Plexus (See Fig 1)



**Figure 1 Diagrammatic representation of Brachial Plexus anatomy**

The brachial plexus innervates the upper limb. It originates from the anterior rami of the lower four cervical and first thoracic spinal nerve roots (C5-8, T1). The five roots emerge from the intervertebral foramina to form the superior (C5-6), middle (C7) and inferior (C8-T1) trunks. The trunks enter the floor of the posterior triangle of the neck between scalenus anterior and scalenus medius muscles. They are covered by an extension of the prevertebral fascia, known as the axillary sheath. The trunks divide into anterior and posterior divisions behind the clavicle. Passing over the outer border of the first rib the divisions combine to form three cords, which are named according to their relation to the axillary artery – lateral, medial and posterior. The posterior divisions form the posterior cord, and the anterior divisions form the lateral and medial cords which supply the flexor aspects of the forearm. The cords divide at the level of the lateral border of pectoralis minor, giving rise to the terminal branches. It is at this level that the axillary brachial plexus block is performed.

Knowledge of the arrangement of the nerves around the axillary artery is integral to performing this block. With the arm out in the “anatomical position” the median nerve usually lies superior to the artery, the ulnar nerve inferiorly and the radial nerve posterior to the artery. The musculocutaneous nerve lies outside the sheath and is usually superior and lateral to the artery. (See Fig 2)



**Figure 2. Cross-sectional view of the arrangement of nerves around the right axillary artery**

### **Median Nerve**

Arising from the medial and lateral cords, the median nerve lies superior and medial to the axillary artery (Figure 2). It supplies the flexor muscles of the forearm (except flexor carpi ulnaris), opponens pollicis, abductor pollicis brevis and 1<sup>st</sup> and 2<sup>nd</sup> lumbricals. Sensory fibres supply the palmar surface of the lateral three and a half fingers and their nailbeds (Figure 3). It has no branches above the elbow.

### **Ulnar Nerve**

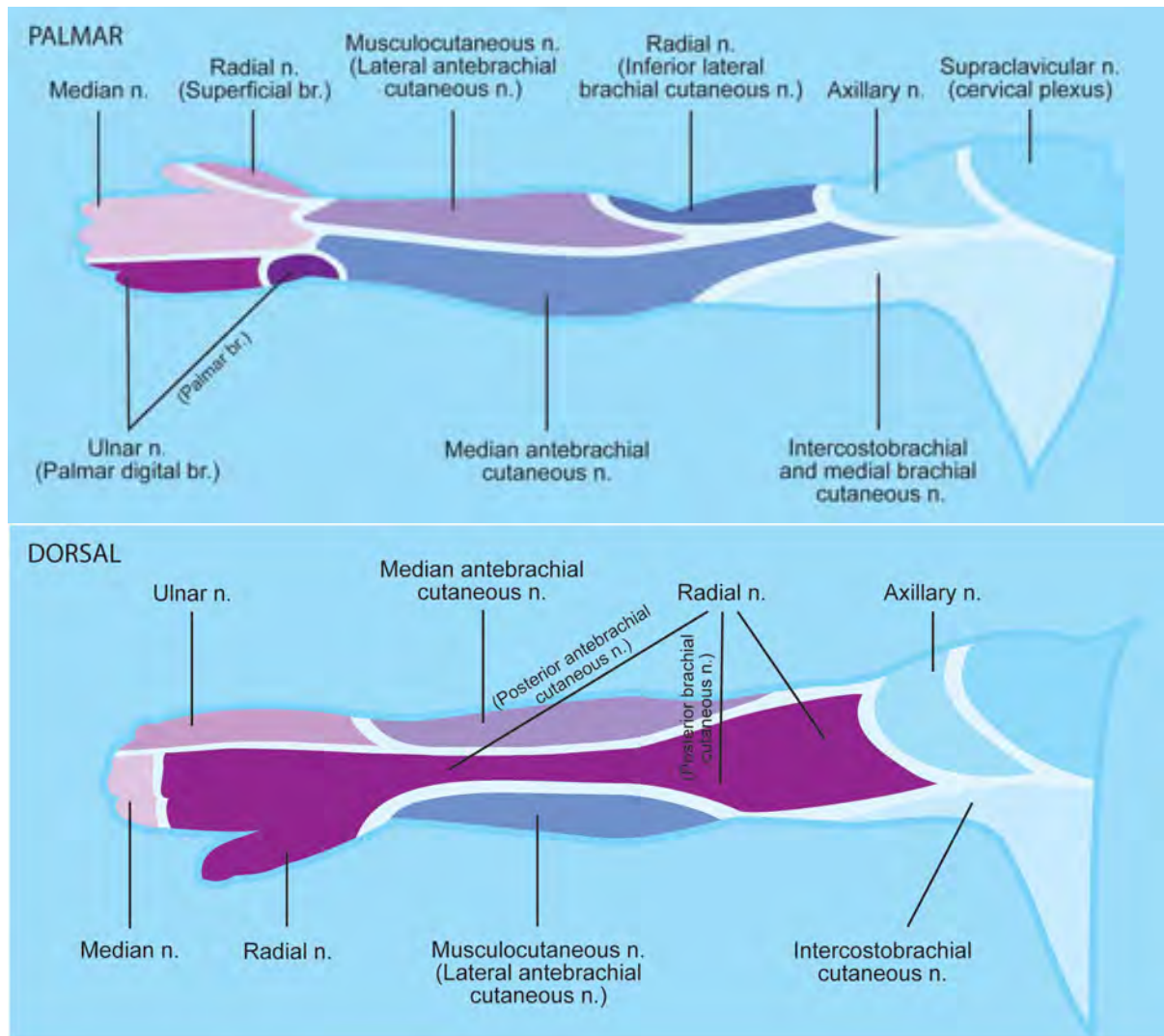
The terminal branch of the medial cord forms the ulnar nerve. It supplies the elbow joint, flexor carpi ulnaris, half of flexor digitorum profundus and the small muscles of the hand (the interossei, 3<sup>rd</sup> and 4<sup>th</sup> lumbricals, adductor pollicis and muscles of the hypothenar eminence). The nerve provides cutaneous sensation for the medial one and a half fingers (Figure 3).

### **Radial Nerve**

Formed by the terminal branch of the posterior cord, the radial nerve exits the axilla beneath teres major and between the humerus and long head of triceps. It travels in the posterior compartment of the upper arm. The radial nerve supplies triceps, brachioradialis the extensor muscles of the forearm. Sensory fibres supply the skin of the lateral aspect of the arm, posterior forearm and web space between thumb and first finger (Figure 3).

### **Musculocutaneous Nerve**

Formed from the lateral cord, it pierces coracobrachialis and lies between biceps and brachialis, supplying each of these three muscles. It then continues as the lateral cutaneous nerve of the forearm. The nerve lies outside the fascial sheath and therefore needs to be blocked separately. Failure to block this nerve can lead failed anaesthesia over the radial border of the forearm and thenar eminence, and tourniquet pain.



**Figure 3: Cutaneous nerve supply of the upper limb**

## TECHNIQUES

Fully prepare the equipment and patient, including consent. Also ensure iv access, monitoring and full resuscitation facilities. For a more detailed explanation on preparation see ATOTW 134 “Peripheral nerve blocks - Getting started”.

Prepare the skin with anti-septic solution and infiltrate local anaesthetic into the skin at the needle insertion site.

### Positioning of Patient

The patient should be lying supine with the arm abducted to 90° and the elbow flexed to 90°. The head should be rotated away from the side to be blocked. Avoid excessive abduction of the arm in order to facilitate palpation of the axillary arterial pulse and avoid stretching of the brachial plexus. Stretching may increase the risk of nerve damage by preventing nerves from rolling away from the needle.

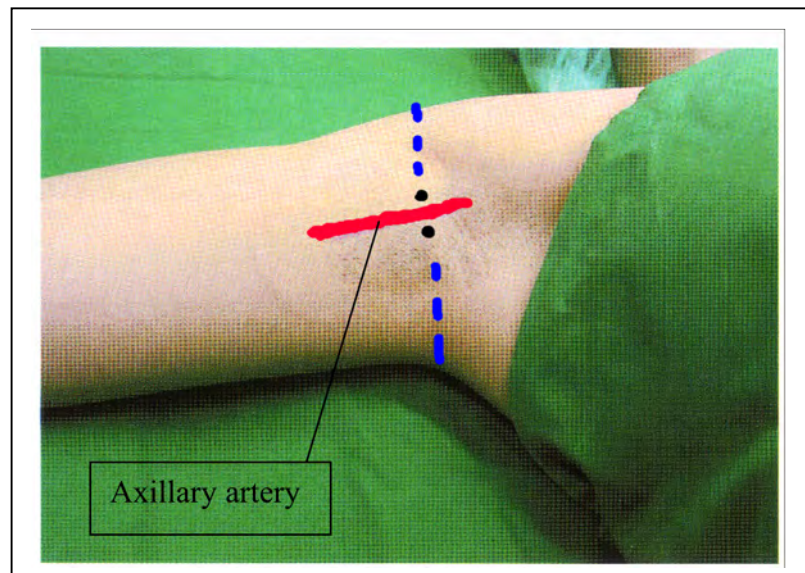
### Landmarks

- Axillary artery
- Apex of the axilla
- Palpate the artery at this point

The relationship of the 4 main nerves to the artery position are shown in Figure 2. It must be remembered that the musculocutaneous nerve is outside the sheath that contains the other three nerves.

### Multi-stimulation Approach

Attach a peripheral nerve stimulator to the patient, using the desired settings, such as current 1 mA, frequency 1Hz, pulse width 0.1ms. Infiltrate the skin with LA above and below the artery. See Figure 4.



**Figure 4. Surface anatomy of the axilla**

Bearing in mind the relationships of the four main nerves, start below the artery and locate the radial and ulnar nerves. Follow this by locating the median and musculocutaneous nerves above the artery. The typical motor responses are shown below:

Radial Nerve = Wrist and finger extension

Ulnar Nerve = Thumb adduction, and flexion of 5<sup>th</sup> finger

Median Nerve = Flexion of fingers

Musculocutaneous Nerve = Elbow flexion

### *Single vs multiple stimulation*

Block success is highest with stimulation of all four nerves, and nearly as good with three (radial, musculocutaneous and median). Less successful blockade is obtained when just one or two nerves are located.

### *Intraneural injection*

Signs that the injection is not placed intraneurally are: the absence of a motor response at a stimulus below 0.2mA, abolition of motor response on injection of LA and no resistance or pain on injection. In theory this will reduce the risk of nerve damage.

### Trans-arterial approach

Deliberately transfixing the axillary artery and placing LA drug deep and superficial to it will result in blockade of radial, ulnar and median nerves. The musculocutaneous will not be blocked as it outside the sheath.

## Paraesthesia approach

Where peripheral nerve stimulators are not available the paraesthesia technique can be used. This relies on demonstrating paraesthesia in the distribution of the nerves to be blocked. See figures 2 & 3 above.

## Intercostobrachial Nerve

This is the lateral cutaneous branch of the 2<sup>nd</sup> intercostals nerve. It supplies sensation to the skin of the axilla and the upper medial and posterior part of the arm. The nerve lies superficially and can be easily blocked to help with upper arm tourniquet pain.

Infiltrate LA in an arc across the floor of axilla, from the superior margin of the biceps at the anterior axillary line to the border of triceps.

Volume 5-8ml.

## LOCAL ANAESTHETIC

**Table 1: Local Anaesthetics used for an Axillary Brachial Plexus Block**

DRUG	ADULT DOSE	TIME TO ONSET OF EFFECT	Duration of action
Prilocaine	40mls of 1% with 1:200,000 adrenaline	30-40 mins	Surgery up to 2 hours Analgesia up to 4-8 hours
Lidocaine	30mls 2% with 1:200,000 adrenaline	15-30mins	Surgery up to 2 hours Analgesia up to 3-6 hours
Bupivacaine/ Levobupivacaine	30mls of 0.375% plain (Max 2mg/kg) with/without 1:200,000 adrenaline	30-60 mins	Surgery up to 6 hours (limited by tourniquet pain in awake patient) Analgesia up to 18-36 hours
Ropivacaine	30mls 0.5-0.75%	30-40 mins	Surgery up to 6 hours (limited by tourniquet in awake patient) Analgesia up to 12-18 hours

## CONTRAINDICATIONS

### Absolute Contraindications:

Patient refusal  
Allergy to local anaesthetic  
Localised infection

### Relative Contraindications:

Anti-coagulation or bleeding diathesis

## COMPLICATIONS

Block failure - in experienced hands success can be up to 98%

Bleeding and haematoma  
Inadvertent vascular injection  
Infection

Nerve damage - this can result from direct trauma, haematoma or high concentrations of LA and vasopressor. Incidence ranges from 1 in 2 000 to 1 in 50 000

## IMPORTANT POINTS:

- Remember to fully prepare the patient and equipment
- Multi-stimulation results in a higher success rate
- Remember to separately block the musculocutaneous nerve
- Remember to always aspirate before injecting LA

## ANSWERS TO QUESTIONS

- a. False - the musculocutaneous nerve lies outside the axillary sheath, it pierces coracobrachialis and lies between biceps and brachialis. It is easily missed (especially when using the trans-arterial approach) and must be blocked separately.
  - b. False – The brachial plexus is formed from the anterior nerve roots of C5-T1
  - c. True
  - d. False – The ulnar nerve supplies cutaneous sensation for the medial one and a half fingers, and supplies the elbow joint, flexor carpi ulnaris, half of flexor digitorum profundus and the small muscles of the hand (the interossei, 3<sup>rd</sup> and 4<sup>th</sup> lumbricals, adductor pollicis and muscles of the hypothenar eminence). It is the radial nerve which supplies the extensor muscles of the forearm.
- 2) Patient refusal, allergy to local anaesthetic (rare) and localised infection over the injection sites are all absolute contraindications to axillary plexus blocks. Coagulopathies or drugs with anti-coagulant action are relative contraindications and should be considered on a risk/balance basis for the patient concerned.
- 3)
  - a. True - Intra-neural injection is less likely when no motor response is elicited with a peripheral nerve stimulator threshold current of <0.3mA. A threshold less than this is likely to increase intra-neural injection and potentially nerve damage.
  - b. True
  - c. True
  - d. True

## WEBLINKS

<http://totw.anaesthesiologists.org/2009/05/18/peripheral-nerve-blocks-getting-started-134/>

<http://nysora.com/>

<http://www.cochrane.org/reviews/en/ab003842.html>

<http://www.nerveblocks.net/>

[http://www.usra.ca/sb\\_axillary](http://www.usra.ca/sb_axillary)

## REFERENCES and FURTHER READING

Handoll H, and Koscielniak-Nielsen ZJ, Single, Double, or Multiple Injection Techniques for Axillary Brachial Plexus Block for Hand, Wrist, or Forearm Surgery; *Anesth Analg* 2006; 103(1):248

Neal JM, Hebel JR, Gerancher JC, Hogan QH, Brachial Plexus Anesthesia: Essentials of our current understanding, *Regional Anesthesia and Pain Medicine*, 2002; 27(4); 402–428

Nicholls B, Conn D, Roberts A, Abbott Pocket Guide to Practical Peripheral Nerve Blockade. July 2006

D.L. Brown, Atlas of Regional Anaesthesia, 3<sup>rd</sup> edition, 2005, Saunders

## Acknowledgments

Illustrations by Edwina Kelly