



# Management of Head Injuries

## ANAESTHESIA TUTORIAL OF THE WEEK 46

### 12TH MARCH 2007

---

Bilal Ali and Stephen Drage  
Contact: [bilalali21@hotmail.com](mailto:bilalali21@hotmail.com)

---

#### Self Assessment Questions

1. A 21 year old male is brought into the Emergency Department (ED) on a Saturday night following a night out. His friends report that he has had over 20 units of alcohol over the past 3 hours, and was found passed out outside a nightclub. He was unrousable and brought to hospital by ambulance. He has some blood on his face from a small scalp wound and is found to have blood in his right ear, but no bruising or other obvious injury. He has a GCS of 6/15 when you see him. What is your plan?
2. You are called to see a 4 year old child who is with his mother in the ED. Four days previously his mother reports that he was playing on the bed with his sister and fell off. Since then he has repeatedly vomited and has been unusually sleepy. You find his GCS to be 11/15, he is difficult to rouse and is vomiting. What is your plan?
3. A 50 year old man assaulted 4 hours earlier has been found to have an acute subdural haemorrhage on a CT scan of his head. He had a GCS of 15/15 on arrival, but is now confused and opens his eyes to speech, giving a GCS of 13/15. Would you intubate this patient prior to transfer to the regional neurosurgical centre?
4. A 75 year old woman presents to the ED with her husband. She was found lying on the floor at home by her husband. She is normally relatively fit and well, with a past medical history of atrial fibrillation, for which she takes digoxin and warfarin. She has had 4 days of intermittent haematuria with offensive urine and has a GCS of 14/15. Her confusion worsens and she is combative. She has a blood white cell count of  $15 \times 10^9$  and her urine is positive for blood, glucose and protein. Are there any further investigations required?
5. The following are all indications for intubation following a head injury prior to transfer (true or false):
  - a. a GCS of 12/15
  - b. a PaO<sub>2</sub> of less than 13kPa (99mmHg) on oxygen
  - c. loss of laryngeal reflexes
  - d. seizures
  - e. a PaCO<sub>2</sub> of 4.6kPa (35mmHg)

#### Introduction

Trauma is now the leading cause of death in most developed countries in the 18-40 age groups and head injury is a major contributing factor. The World Health Organisation estimates that 300 people per day are killed due to trauma on Africa's roads. The most common causes of head injury are falls, road traffic accidents and assaults, with young men and children the most affected. In the UK, around one million people per year attend Emergency Departments due to head injury.

Head injury is defined by the National Institute for Clinical Excellence in the UK (NICE, [www.nice.org.uk](http://www.nice.org.uk)) as any trauma to the head other than superficial injuries to the face. Mild head injury makes up around 90% of all cases (GCS 13-15), moderate 5% (GCS 9-12) and severe head injury 5% (GCS  $\leq 8$ ).

Head injury is a major cause of long-term disability and economic loss to society. Much of the neurological damage resulting from a head injury does not occur immediately, but in the minutes, hours and days that follow. It is for this reason that so much emphasis is placed on immediate management of head-injured patients. The primary injury is due to irreversible mechanical injury, but secondary injury which leads to cerebral ischaemia, results from raised intracranial pressure (ICP), hypotension, hypoxia, anaemia, seizures, hypoglycaemia and hyperthermia. Prevention and correct management of these complications improves outcome from head injury.

### **Principles of management**

The main aim of assessment and management of head-injured patients is to maintain adequate cerebral blood flow (CBF) and to avoid cerebral ischaemia and hypoxia. In patients with head injury the normal autoregulation of CBF is lost and CBF becomes proportional to cerebral perfusion pressure (CPP), which in turn is directly determined by both the mean arterial pressure (MAP) and the intracranial pressure (ICP):

$$\text{CPP} = \text{MAP} - \text{ICP}$$

The cranium is a rigid structure with a fixed capacity, which contains 80% brain, 10% blood and 10% CSF. These structures are all non-compressible; therefore an increase in the volume of any of these contents, unless coupled by a decrease in volume of another, results in an increase in ICP.

The main mechanisms of maintaining CPP are to ensure adequate MAP (by the use of fluids and vasopressors) to prevent excessive rises in ICP. In normal individuals the ICP is 0-10mmHg and this is largely determined by autoregulation of CBF (i.e. the amount of blood in the cranium). Vasoconstriction or vasodilatation of cerebral vessels occurs in response to changes in MAP, PaO<sub>2</sub>, PaCO<sub>2</sub> and blood viscosity. Although these responses may be obtunded in head injury, prevention of secondary brain injury involves manipulation of these variables. An increase in PaCO<sub>2</sub> causes vasodilatation and an increase in CBF, which may increase ICP; a decrease in PaCO<sub>2</sub> causes vasoconstriction leading to decreased CBF and ICP. Thus inappropriate hyperventilation may cause ischaemia. A fall in PaO<sub>2</sub> causes vasodilatation with a consequent rise in ICP.

## Initial assessment

Patients presenting with significant head injury may have multiple injuries. The history of the mechanism of injury is useful in determining the potential extent of the head injury and is also an indication of the likelihood of other injuries. For example, the driver of a vehicle travelling at 60mph and not wearing a seatbelt raises the suspicion of major head injury and significant extracranial injury.

Initial management should be guided by protocols suggested by Advanced Trauma Life Support (ATLS) or Primary Trauma Care (PTC, [www.primarytraumacare.org](http://www.primarytraumacare.org)). Injury to the cervical spine should be assumed from the start of assessment. Brain injury may be worsened by airway or circulatory compromise; use the 'ABCDE' approach to identify and treat life-threatening injuries early.

Once the patient has a secure airway, is adequately oxygenated and has a stable cardiovascular system, where available consideration should be given to transfer to a neurosurgical unit. When discussing the case with the neurosurgeon it is important to clearly convey the mechanism of injury, any other injuries and the results of a brief neurological assessment. The surgeon will want to know the history, the Glasgow Coma Score (GCS) at the scene, on arrival at your hospital and the current GCS, the papillary size and reaction and whether you can elicit any signs suggesting a collection of blood on one side of the cranial cavity ('lateralising' signs).

## The Glasgow Coma Scale

The GCS is the globally accepted method of quantifying and recording the neurological status of the head-injured patient. It is also useful in determining any improvement or deterioration in neurological function and facilitates accurate communication between health professionals on different sites. The scale is made up of three sections, with a minimum score of 3 and a maximum of 15. The best score in each section should be recorded (i.e.: if the patient localises with the right arm but extends on the left then the best motor score is 5/6). The components of GCS are:

### Eye Opening

- Spontaneously 4
- To speech 3
- To pain 2
- None 1

### Verbal response

- Orientated 5
- Confused 4
- Inappropriate 3
- Incomprehensible 2
- None 1

### Motor response

- Obeys commands (for movement) 6
- Purposeful movement to painful stimuli ('localises') 5
- Purposeful movement to painful stimuli ('localises') 4

- Abnormal (spastic) flexion, decorticate posture 3
- Extensor (rigid) response, decerebrate posture 2
- None 1

The standard painful stimulus applied to the patient should allow the differentiation of purposeful movement ('localising'), from withdrawal and abnormal flexion. Strictly speaking true localisation or purposeful movement should follow a stimulus from one site to another. Squeezing/pinching the trapezius muscle and supra-orbital pressure are preferred stimuli. Nail bed pressure and sternal rub are less reliable and not of use in patients with spinal injury. Care must also be taken when assessing motor response in those with a suspected cervical spine injury, as any response may cause the response to attempt to move their head.

The **Blantyre Coma Score** was originally designed for treatment of children with malaria, but is useful for assessment of children with head injury:

**Eye movements**

- Watches or follows (e.g. mother's face) 1
- Fails to watch or follow 0

**Motor response**

- Purposeful movement to painful stimuli ('localises') 2
- Withdraws from pain 1
- No response or inappropriate response 0

**Verbal response**

- Cries appropriately with painful stimulus, or if verbal speaks 2
- Moan or abnormal cry with painful stimulus 1
- No vocal response to painful stimulus 0

**Management**

The main aims of management of any moderate or severe injury head injury are initial assessment and resuscitation, deciding whether ventilatory support is necessary and establishing a diagnosis (with a CT head scan where available.) Early contact with specialist neurosurgical units is vital; they will often advise on specific therapies. Early transfer, when indicated, is also important. The Association of Anaesthetists of Great Britain and Ireland suggest a maximum time of 4 hours between injury and surgery. Throughout this process management should be equal to that in an ICU, directed at maintaining the MAP and CPP and preventing rises in ICP.

**Airway**

The main concern is whether the patient is able to protect their airway and therefore whether intubation is necessary. Indications for intubation include:

- GCS  $\leq$  8
- Risk of raised ICP due to agitation (i.e. sedation required)
- Inability to control/protect the airway or loss of protective laryngeal reflexes

- A fall of 2 or more points in the motor component of the GCS
- In order to optimise oxygenation and ventilation
- Seizures
- Bleeding into mouth/airway
- Bilateral fractured mandible

This is not an exhaustive list and clinical judgement is important. If there is doubt it is safest to intubate and consider early extubation rather than delay intubation and risk secondary brain injury from hypoxia.

Rapid sequence intubation is almost always required. Maintain cervical spine immobilisation during intubation, unless the cervical spine has been cleared by meeting clinical and radiological criteria. Avoid the temptation to withhold drugs in profoundly unconscious patients; some hypnosis and analgesia is required to obtund the rise in ICP that is inevitably caused by laryngoscopy. Propofol, etomidate, benzodiazepines and barbiturates all reduce ICP and are preferentially used. Ketamine produces a rise in ICP, but may be the only induction agent available in certain countries. Opioids and depolarising neuromuscular drugs do not increase ICP and the fasciculation caused by suxamethonium only causes a transient rise in ICP. Nitrous oxide may also cause a rise in ICP by increasing cerebral blood flow.

Detection of cervical spine injuries is beyond the scope of this tutorial but all patients with head injury should have plain X-rays of the cervical spine and some may require a CT scan.

### **Breathing**

Hypoxaemia is associated with a significant increase in mortality. A drop in PaO<sub>2</sub> below 8kPa (about 60mmHg) causes an increase in CBF and ICP. Targets for gas exchange should be a PaO<sub>2</sub> greater than 13kPa (100mmHg) and a PaCO<sub>2</sub> in the low-normal range - usually 4.5-5.0 kPa (35-39mmHg). Prolonged hyperventilation is not recommended since cerebral vasoconstriction and ischaemia may result, however short bursts of hyperventilation (a few minutes) may help to control episodes of high ICP.

### **Circulation**

The loss of the autoregulation of CBF can result in a reduction in oxygen delivery. Maintenance of the MAP and CPP is essential; resuscitation and treatment of life-threatening circulatory instability should take precedence over neurosurgical interventions. This may require surgery for haemorrhage control.

Use fluids, and where necessary vasopressors, to achieve a MAP greater than 80-90mmHg. This figure is recommended as a guide until ICP monitoring is established, and assumes that the ICP is 20mmHg and therefore ensures a CPP of at least 60-70mmHg (since CPP = MAP – ICP). Once ICP monitoring is established then treatment is targeted at maintaining CPP 60-70mmHg. Aiming for higher CPP targets has been associated with adverse cardiorespiratory outcomes.

Ideally the MAP is measured using an arterial line and a central venous catheter may be useful for monitoring and the administration of vasopressors. A urinary catheter allows

monitoring of urine output and fluid balance and is necessary if mannitol or other diuretics are used.

### Monitoring intracranial pressure

Some clinical signs are suggestive of raised ICP. These include:

- Headache
- Dizziness
- Loss of consciousness
- Confusion
- Hypertension and bradycardia (Cushing's reflex)
- Nausea
- Vomiting
- Focal weakness or paresthesia
- Other focal neurological signs
- Change or asymmetry pupils

### Measurement of ICP

ICP can be measured in the following ways.

Method	Benefits	Disadvantages
Intraventricular catheter ('EVD' or external ventricular drain)	<ul style="list-style-type: none"> <li>• Gold Standard method</li> <li>• Allows CSF drainage to lower ICP</li> <li>• Calibration possible</li> </ul>	<ul style="list-style-type: none"> <li>• Most invasive method</li> <li>• High infection rate</li> <li>• May be difficult to insert</li> <li>• Simultaneous CSF drainage and ICP monitoring not possible</li> </ul>
Extradural probe	<ul style="list-style-type: none"> <li>• Low infection rate (no penetration of dura)</li> <li>• Easy to insert</li> </ul>	<ul style="list-style-type: none"> <li>• Limited accuracy</li> <li>• Relatively delicate</li> </ul>
Subarachnoid probe	<ul style="list-style-type: none"> <li>• Low infection rate</li> <li>• No brain penetration</li> </ul>	<ul style="list-style-type: none"> <li>• Limited accuracy</li> <li>• High failure rate</li> </ul>
Intraparenchymal probe	<ul style="list-style-type: none"> <li>• Low infection rate</li> </ul>	<ul style="list-style-type: none"> <li>• Measures local pressure</li> </ul>
Transcranial Doppler	<ul style="list-style-type: none"> <li>• Non invasive</li> </ul>	<ul style="list-style-type: none"> <li>• Limited precision</li> </ul>
Lumbar CSF pressure	<ul style="list-style-type: none"> <li>• Extracranial procedure</li> </ul>	<ul style="list-style-type: none"> <li>• Inaccurate reflection of ICP</li> <li>• May be dangerous when brain oedema present</li> </ul>
Tympanic membrane displacement	<ul style="list-style-type: none"> <li>• Non-invasive</li> </ul>	<ul style="list-style-type: none"> <li>• Insufficient accuracy</li> </ul>

### Management of raised ICP

### **Improving venous drainage from the brain**

- **Elevation of the head** of the bed to 30°
- Good neck alignment – **head in the neutral position**
- Ensuring ties holding the endotracheal tube in place do not compress the neck veins. Alternatively **tape the tube** using ‘trouser-legs’.
- Where possible immobilise the patient’s cervical spine with **sandbags and tape** rather than restrictive neck collars

### **Reducing cerebral oedema**

- Use **mannitol** (an osmotic diuretic) 0.5-1g/kg (= 5-10ml/kg of 10% or 2.5-5ml/kg of 20% mannitol). Some units use small aliquots of **hypertonic saline** as an alternative
- Use **furosemide** (a loop diuretic) 0.5-1mg/kg
- Maintain **serum Na<sup>+</sup>** in the range 140-145mmol/l

### **Reduction of the cerebral metabolic rate for oxygen**

- **Close temperature regulation.** Avoid hyperthermia, but do not actively induce hypothermia.
- **Use of sedation and anaesthetic drugs.** Ensure that the patient is appropriately sedated and has received adequate analgesia.
- If the patient has a witnessed seizure loading with an **anticonvulsant**, usually phenytoin 18mg/kg, should be considered.
- In cases of intractable raised ICP, a **thiopentone infusion** can be used to reduce the cerebral metabolic rate to a basal level. This is identified on EEG monitoring as ‘burst suppression’.

### **Reducing intracranial blood volume**

- Consider whether the patient has suffered a new or worsening intracranial haemorrhage. Are there any new or lateralising signs? Is a **repeat CT scan** required?
- Hyperventilation can be used to reduce the PaCO<sub>2</sub> as a temporary measure, but cerebral ischaemia may result if this is prolonged.
- The final resort if ICP remains raised is to perform a **decompressive craniectomy**.

### **Reducing CSF volume**

- In a neurosurgical centre, use of an **external ventricular drain (EVD)** allows drainage of CSF to relieve raised ICP

## Transfer to Neurosurgical Unit

Ideally local guidelines will guide you on who to talk to in order to make a referral. If the patient's condition changes significantly seek further advice. Electronic transfer of CT images may lessen the delay in referral.

Full resuscitation and stabilisation of the patient and all injuries must be completed prior to transfer. A doctor with appropriate training and experience should oversee the transfer of the patient, the goal being continuous management to the standard available in the ICU. Ideally monitoring for transfer should include ECG, invasive blood pressure, pulse oximetry, urinary catheter/output and capnography. Pupillary size and reaction to light should also be monitored. It is useful to check an arterial blood gas prior to departure and to correlate the PaCO<sub>2</sub> to the end-tidal value. As with all transfers, think what may go wrong and check you have the facilities to deal with it en route.

## Types of injury

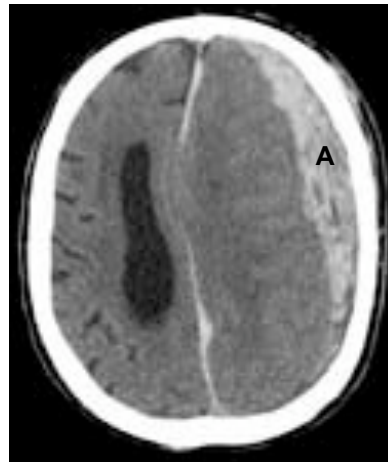### Traumatic subarachnoid haemorrhage

This is the most common type of intracranial haemorrhage. Blood is seen in the CSF and subarachnoid space. It is often caused by tearing of small subarachnoid blood vessels. Vasospasm may complicate traumatic subarachnoid haemorrhage and the amount of blood is related to the patient's GCS and outcome.

### Acute subdural haemorrhage

This type of injury is often caused following forceful acceleration-deceleration events. Blood is seen on CT between the dura and the brain. Rapid neurosurgical intervention is often required, necessitating rapid transfer. On CT scan the border of the haematoma next to brain tissue is typically concave towards the midline.

Figure 1: CT scan showing large left fronto-parietal subdural haematoma (A), with midline shift and compression of the left lateral ventricle.



### **Epidural (extradural) haemorrhage**

This is seen in up to 1% of cases. Blood is seen on CT between the skull and the dura. The classical presentation is of a patient who initially has loss of consciousness and is then lucid before deteriorating again. Extradurals often occur in conjunction with skull fractures, particularly over the course of the middle meningeal artery. Prognosis is good if surgery is performed promptly. On CT scan the border of the haematoma next to brain tissue is typically convex towards the midline.

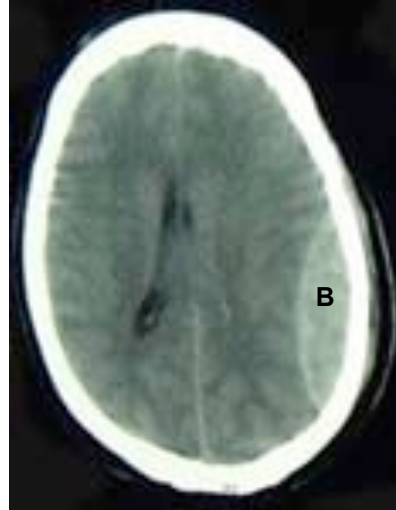


Figure 2: CT scan showing a left occipito-parietal extradural haematoma (B).

### **Intracerebral haemorrhage**

This is an injury deep within the brain itself, and is caused by shearing forces between the cranium and brain. It is most common around the frontal and temporal regions, with 50% of cases suffering loss of consciousness on impact.

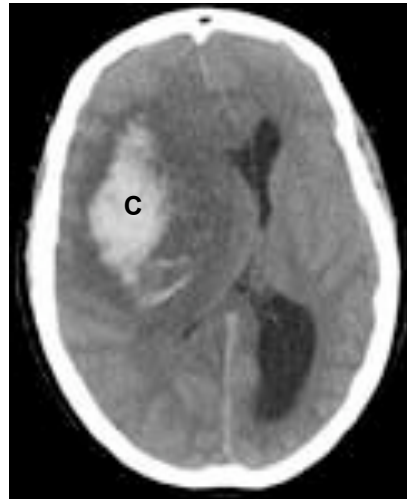
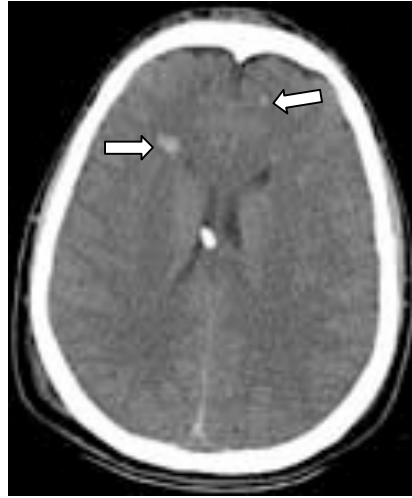

Figure 3: CT scan showing a fronto-parietal intracerebral haematoma (C) with surrounding oedema and midline shift

### Diffuse Axonal Injury

This is the primary lesion in around 40-50% of severe head injuries, and is secondary to shearing and tensile forces. The prognosis is linked to the clinical cause, with a prolonged coma suggesting severe, irretrievable injury.

Figure 4: CT scan showing diffuse axonal injury with frontal petechial haemorrhages (arrows)



### Further reading

1. **Recommendations for the safe transfer of patients with brain injury.** The Association of Anaesthetists of Great Britain and Ireland (2006).
2. **NICE Guidelines.** Head injury: triage, assessment, investigation and early management of head injury in infants, children and adults (2003) <http://www.nice.org.uk>
3. **Primary Trauma Care.** Trauma resuscitation guidelines for resource limited countries. [www.primarytraumacare.org](http://www.primarytraumacare.org)
4. **Brain Trauma Foundation.** Evidence based guidelines for head injury management. [www.braintrauma.org](http://www.braintrauma.org)

### Answers to Self Assessment Questions

If you work in a hospital where CT scanning is available, the following indications for performing a head scan in head-injured patients are provided by the National Institute for Clinical Excellence (NICE, [www.nice.org.uk](http://www.nice.org.uk)) in the UK:

- GCS less than 13 at any point since injury
  - GCS equal to 13 or 14 at 2 hours after injury
  - Suspected open or depressed skull fracture
  - Any sign of basal skull fracture
  - Post-traumatic seizure
  - Focal neurological deficit
  - More than one episode of vomiting
  - Amnesia of events, for greater than 30 minutes before impact
1. This patient represents a common clinical scenario in many countries around the world. When large amounts of alcohol have been ingested neurological assessment is difficult. **Although this patient's condition may be attributable to alcohol, it is**

**essential not to make this assumption and risk missing a serious neurological injury.** The patient's fall with resultant head injury was unwitnessed and assault cannot be excluded. With a GCS of 6/15 and therefore a poorly maintained airway, an unknown mechanism of injury and a haemotympanum, he should be managed as a severe head injury until proven otherwise. Therefore appropriate anaesthesia, intubation, ventilation and a CT head (where available) is indicated. In many cases such as this, the CT is normal and the patient will be successfully woken and extubated within a few hours. Where CT scanning is not available a skull X-ray should be considered (a basal skull fracture will increase the suspicion of underlying brain injury).

2. This young child has an altered GCS and is vomiting a number of days after a head injury. A CT head scan is warranted. With such a delayed presentation the need for intubation and ventilation is not clear-cut. The child should be closely monitored and managed in conjunction with the paediatricians. The decision to sedate and intubate must be made after considering his clinical progress of the next few hours, the results of the CT and the need for transfer. Also remember that this child represents a delayed presentation of trauma in a child and the possibility of non-accidental injury should be considered. A full history from the parents and, where possible, the child should be taken. Signs of other injuries (old and new) or repeated hospital visits should also be investigated.
3. This patient has an established neurosurgical diagnosis and his GCS has dropped by 2 points. The presence of a subdural collection is not an absolute indication for intubation prior to transfer, but it should be considered. You must be confident that he will not deteriorate further during transfer if you are to avoid pre-emptive intubation. The distance to the neurosurgical centre, the rapidity of deterioration and the facilities for intubation and transfer at your hospital are factors to consider. If you are unclear, phone the neurosurgeon for advice: if they plan immediate surgery anyway, little is lost by intubating the patient for transfer. They may suggest a repeat CT scan to assess progression of the subdural haematoma.
4. This 75 year old patient was admitted under the medical team and treated for a urinary tract infection. However, her confusion worsened, until she was unmanageable on the ward. The ICU team were called and she was sedated, intubated and ventilated. Reviewing her history the fall was again noted, and on further questioning the patient's husband stated that she may have actually fallen down the stairs. Her treatment with warfarin increased the suspicion of intracranial pathology and a CT scan of her head was requested. This showed an acute subdural haemorrhage that required neurosurgical evacuation. This case highlights that you should have a low threshold for suspecting intracranial bleeding in anticoagulated patients, who have suffered even a minor head injury. It also emphasises the importance of taking a full history in order to provide the clues to diagnosis, particularly when referral to ICU is delayed after the initial hospital presentation.
5.
  - a. False - this is a relative, not absolute, indication
  - b. True
  - c. True
  - d. True
  - e. False